

SOUTHWESTERN  
INSTITUTE OF FORENSIC SCIENCES  
5230 Medical Center Drive  
Dallas, Texas 75235

COPY

Case No. 1811-96-1291JM

Name: Routier, Devon

Age: 6

Race: White

Sex: Male

Date of Death: 06 JUN 1996

Date of Examination: 06 JUN 1996

Time of Death:

Time of Examination: 1:10 pm

Pronounced at: 5801 Eagle Drive  
Rowlett, Dallas County, Texas

AUTOPSY REPORT:

ORGAN WEIGHTS:

Brain	1470 g	R. Lung	103 g	R. Kidney	50 g
Heart	111 g	L. Lung	87 g	L. Kidney	50 g
Liver	600 g	Spleen	50 g	Thymus	30 g

EXTERNAL EXAMINATION:

The body is identified by a toe tag. Photographs and footprints are taken. The body is not embalmed. The hands and feet are bagged.

The body is received in a body bag on a white sheet. The body is wearing one "Power Ranger" pair of shorts. A "Power Ranger" pillowcase and pillow are submitted. Also noted is one black and white bed cover. All of these items are retained. Left on the body is one cloth necklace with beads and a metal shark tooth-type pendant.

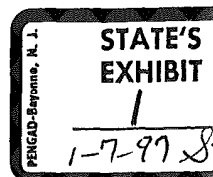
The body is that of a well-developed, well-nourished, white male child appearing the stated age of 6 years. The body measures 46 inches (116.8 cm) in length and weighs 46 pounds (20.9 kg).

Rigor mortis is generalized and postmortem lividity is purple and blanching on the posterior aspect of the body. The body is cool to touch.

The scalp hair is brown. No beard or mustache are noted. The irides are blue-green with no petechiae noted. The teeth are natural. The neck, chest, abdomen, back, and extremities are unremarkable except for the injuries noted. The external genitalia are those of a circumcised male child.

EVIDENCE OF THERAPY:

None.



Name: Routier, Devon

COPY

EVIDENCE OF INJURY:

SHARP FORCE INJURIES:

The body shows four separate sharp force injuries which are numbered arbitrarily for the purposes of description without regard to severity or chronological sequence.

STAB WOUND NUMBER ONE:

There is a stab wound of the left upper chest located 12-1/2 inches from the top of the head and 2 inches to the left of midline. The stab wound measures 2 inches in length and has a sharp and blunt angle. The stab wound perforates the left chest wall between the anterior fourth and fifth ribs. The stab wound then perforates the left upper lobe of lung, the pulmonary artery above the pulmonary valve, the right lower lobe of lung, and penetrates into the right posterior chest approximately 1/16 inch. The stab wound penetrates into the right posterior chest between ribs seven and eight. There is corresponding hemorrhage in the posterior chest wall. The stab wound measures 1-3/4 inches in length when measuring the defect in the musculature of the anterior chest wall.

The stab wound direction is front to back, left to right, with essentially no up or down deviation. The maximum estimated depth of penetration is 5 inches.

STAB WOUND NUMBER TWO:

There is a stab wound of the left midportion of the chest located 15 inches from the top of the head and 1 inch to the left of midline. The stab wound measures 2-3/4 inches in length and has a sharp and indeterminate angle. The stab wound perforates the left chest wall in the region extending from rib six to rib seven. Portions of cartilage are perforated. The stab wound measures 2 inches in length when measuring the defect in the chest plate. The stab wound penetrates into the liver.

The direction of the stab wound is front to back, slightly right to left, with essentially no up or down deviation. The maximum estimated depth of penetration is 2-1/2 inches.

INCISED WOUND NUMBER THREE:

There is an incised wound of the left forearm located 21-1/2 inches from the top of the head, 11-3/4 inches below the top of the shoulder, and 2-3/4 inches above the wrist. This incised wound measures 1-1/4 inches in length and has indeterminate angles. The estimated depth of penetration is 1/8 inch. The stab wound involves only the soft tissue of the left arm.

STAB WOUND NUMBER FOUR:

There is a stab wound of the posterior left thigh located 29-1/2 inches from the top of the head and 1-1/2 inches to the left of midline of the left leg. The

Name: Routier, Devon

COPY

stab wound measures 3/4 inch in length and has a 3/4 inch depth of penetration. The stab wound involves only the soft tissue of the posterior thigh. Indeterminate angles are noted. The direction of the stab wound is back to front, right to left, and downward.

**ADDITIONAL INJURIES:**

The palmar surface of the left hand shows two 1/16 inch areas of fairly round abrasion. The thenar eminence of the left hand shows an area of bluish contusion that measures 1-1/4 x 1/2 inch. The thenar eminence of the right hand shows a similar bluish contusion that measures 1-1/2 x 3/4 inches in greatest dimension.

There is a 1 x 1/2 inch area of abrasion of the posterior aspect of the right arm below the elbow.

There is a faint linear area of punctate petechial hemorrhage of the left side of the neck that measures 1-3/4 inches in length.

There is a 1/2 inch superficial abrasion of the left upper arm and back region.

There is an area of greenish contusion of the left hip that measures 1/2 inch in greatest dimension.

Two brown contusions that measure 1/4 inch in greatest dimension are noted of the anterior surface of the right lower leg.

**ADDITIONAL FINDINGS:**

The right and left pleural cavities each contain approximately 450 ml of blood. The pericardial sac contains approximately 30 ml of blood.

**INTERNAL EXAMINATION:**

The injuries have been previously described and will not be repeated.

Apart from the features described above, examination of the organs and tissues which comprise the HEAD, CENTRAL NERVOUS SYSTEM, NECK, BODY CAVITIES, CARDIOVASCULAR, RESPIRATORY, HEPATOBILIARY, LYMPHORETICULAR, GENITOURINARY, GASTROINTESTINAL, ENDOCRINE, and MUSCULOSKELETAL SYSTEMS reveals all to be within the usual limits of size, character and position for age, sex, and development.

In particular, it is noted that the stomach is empty. The bladder contains 1 ml of urine. The gallbladder contains 3 ml of bile. The appendix is present.

Name: Routier, Devon

COPY

FINDINGS:

1. Stab wound of the left chest:
  - a. Entrance: Left chest.
  - b. Direction: Front to back, left to right, with essentially no up or down deviation.
  - c. Sharp and blunt angle.
  - d. Injuries: Perforation of the left upper lobe of lung, pulmonary artery, right lower lobe of lung.
  - e. Bilateral hemothoraces.
  - f. Hemopericardium.
  - g. Maximum depth of penetration estimated at 5 inches.
2. Stab wound of the left chest:
  - a. Entrance: Left chest.
  - b. Direction: Front to back, slightly right to left, with essentially no up or down deviation.
  - c. Indeterminate and sharp angle.
  - d. Injuries: Penetration of the liver.
  - e. Maximum depth of penetration estimated at 2-1/2 inches.
3. Incised wound of the left forearm.
4. Stab wound of the posterior aspect of the left thigh:
  - a. Entrance: Posterior aspect of the left thigh.
  - b. Direction: Back to front, right to left and downward.
  - c. Injuries: Penetration of the soft tissue of the posterior thigh.
  - d. Estimated maximum depth of penetration: 3/4 inch.
  - e. Indeterminate angles.
5. Abrasion of the right posterior forearm.
6. Contusion of the thenar eminence of both hands.
7. Punctate abrasions of the left palmar surface of the hand.
8. Linear abrasion of the left upper arm and back region.
9. Linear area of petechial hemorrhage of the left side of the neck.
10. Contusions, left hip and right lower leg.
11. Associated case number 1810-96.

Name: Routier, Devon

CONCLUSION:

It is my opinion that Devon Routier, a 6-year-old white male, died as the result of multiple sharp force injuries.

MANNER OF DEATH: Homicide.

COPY

TOXICOLOGY:

Blood: Alcohols and Acetone - negative.  
Drug Screen - negative.

Vitreous: Alcohols and Acetone - negative.

*Joni L. McClain MD*

Joni L. McClain, M.D.  
Medical Examiner

*Karen F. Ross*

Karen F. Ross, M.D.  
Medical Examiner

*J. K. Townsend-Parchman MD*

J. K. Townsend-Parchman, M.D.  
Medical Examiner

*Sheila Spotswood*

Sheila Spotswood, M.D.  
Medical Examiner

*Charles B. Odom MD*

Charles B. Odom, M.D.  
Medical Examiner

*J. M. Guileyardo*

J. M. Guileyardo, M.D.  
Deputy Chief Medical Examiner

*Jeffrey J. Barnard*

Jeffrey J. Barnard, M.D.  
Chief Medical Examiner

THE SOUTHWESTERN INSTITUTE OF FORENSIC SCIENCES  
AT DALLAS

Name Devon Routhier Case No. 1811-96

Age \_\_\_\_\_

Date \_\_\_\_\_

